

ORIGINAL PAPER

Bone computed tomography mineral content evaluation in chickens: effects of substances in homeopathic concentration



Sergio Canello¹, Gabriele Gasparini², Patrizio Luisetto¹, Alessandro Di Cerbo^{3,*} and Fabio Pomerri⁴

¹Homeopathic Medical School, Verona, Italy

²Neuroradiology Unit, Ospedale dell'Angelo, Mestre, Italy

³School of Specialization in Clinical Biochemistry, University of Chieti-Pescara, Chieti, Italy

⁴Radiology Oncology Unit, Istituto Oncologico IOV, IRCCS, Padua, Italy

Methods: Ninety-six Cobb race chickens were equally divided in 4 groups and randomly assigned to receive a standard treatment feed + homeopathic concentrations of *Symphytum (S.) officinalis* (9CH), or standard treatment feed + homeopathic concentrations of *Tricalcarea* (4CH), or standard treatment feed + homeopathic concentrations of *Calcareo (C.) carbonica* (30CH) or a placebo (the same feed but without any homeopathic compound) in order to assess the ability of the homeopathic compounds to increase the concentration of calcium hydroxyapatite in the sternal spongy bone tissue. We measured the concentration of calcium hydroxyapatite in the sternal spongy bone tissue of all chickens by means of a computed tomography (CT).

Results: 30%, 36% and 63% increase of sternum spongy-bone mineralization was observed after a 2 years period in the treatment groups with *S. officinalis* (9CH), *Tricalcarea* (4CH) (* $P < 0.05$) and *C. carbonica* (30CH) (** $P < 0.001$) respectively.

Conclusion: Bone mineralization is usually low in battery chickens reared in commercial poultry-sheds, creating a weakness of the whole animal supporting apparatus. Homeopathic preparations with bone-tissue tropism may improve their health quality. *Homeopathy* (2016) 105, 92–95.

Keywords: *Symphytum officinalis*; *Tricalcarea*; *Calcareo carbonica*; Spongy-bone mineralization

Abbreviations: dH = decimal potency; cH = centesimal potency; CT = computed tomography

Introduction

Bone strength of market age poultry, which often suffer from lameness and bone deformities, is of great importance in intensive farming because bone breakage and associated infections contribute to mortality, low productivity, and

carcass condemnations.^{1–4} Moreover, bone weakness and porosity is also correlated with leg weakness and osteoporosis in laying hens as well as with the incidence of bone fragments in deboned meat products, and with discoloration of meat adjacent to bone due to leaching of blood.⁵ Among factors affecting leg abnormalities and bone quality of meat-type fowl growth rate is considered as a major contributor.^{1,6} Thus, bone mineralization becomes an important factor reflecting the status of skeletal health where calcium holds a pivotal role in maintaining it.¹ Mazzuco et al. reported that bone mineral density decrease of the excised tibia of White Leghorns resulted in a bone breakage incidence increase.⁷

Based on such observations the role of nutritional factors, and even homeopathic medicine, might become a

*Correspondence: Alessandro Di Cerbo, School of Specialization in Clinical Biochemistry, University of Chieti-Pescara, Chieti, Italy.

E-mail: Sergio.canello.5@facebook.com, neurorad@ulss12.ve.it, patrizio.luisetto@gmail.com, Alessandro811@hotmail.it, fabio.pomerri@ioveneto.it

Received 22 January 2015; revised 26 March 2015; accepted 11 July 2015

valid alternative to conventional medicine in order to modulate poultry bone strength.

S. officinalis root belongs to the family Boraginaceae and is widely used in Western herbal medicine practice.⁸ It contains carotene, essential oils, vitamin B12, zinc and allantoin which are known to have a healing capacity.^{9,10} *S. officinalis* contains pyrrolizidine alkaloids which are associated with hepatic disease under certain conditions.¹¹ But homeopathic preparations of *S. officinalis* are said to accelerate bone healing, reducing the time to consolidate bone fractures.¹² Moreover literature reports have also ascribed to this root the ability to treat gastrointestinal tract ulcerations, tendon damage and joints disease.¹³ Sakakura et al. also showed that homeopathic solution (6CH) of *S. officinalis* administration increased radiographic bone density and area of bone gain around titanium implants placed in the tibia of 48 rats at 14 and 7 weeks postsurgery.¹⁰

As to Tricalcarea (a mix of *C. fluorica* (CaF_2), *C. phosphorica* ($\text{Ca}_3(\text{PO}_4)_2$) and *C. carbonica* (CaCO_3)), homeopathic solutions of these compounds given to 8 children with epiphysitis in the course of 3 years outdoor showed a very good therapeutic effect already after a 30 days treatment.¹⁴ On the other hand, *C. carbonica* (calcium carbonate) is known to improve bone tissue tropism, even when homeopathically diluted, and clinic symptomatology caused by absorption deficiency or defective mobilisation of calcium.^{15–17} As to *C. phosphorica*, is one of the homeopathic medicines prescribed for bone disease treatment, late bone callus formation, problems with fracture union, bone-deficient and abnormal growth, and for fractures followed by pain and paresis.^{18,19} Further, Senra et al. observed that hypertensive castrated rats treated with *C. phosphorica* had a higher optical density in the bone repair area than with risedronate and *C. fluorica*.²⁰

The present study evaluated the influence of a feed enriched in *S. officinalis*, Tricalcarea and *C. carbonica* in homeopathic dilutions (9CH, 4CH and 30CH, respectively), on the concentration of calcium hydroxyapatite in the sternal spongy bone tissue of cobb race chickens over a 2 years period.

Operative procedures and animal care were performed in compliance with the national and international regulations (Italian regulation D.L.vo 116/1992 and European Union regulation 86/609/EC). The protocol was examined and approved prior to the start of the study by the Veterinary Ethical Review Committee. The recommendations of the ARRIVE guidelines in animal research were also consulted and considered.²¹

Materials and methods

This evaluation was designed as a randomized, placebo-controlled clinical one. Over a period of two years we equally divided 96 newborn chickens in 4 groups ($n = 24$) which were randomly assigned to receive: 1) standard treatment feed [yellow corn (55–60%), soya (30–35%), gluten (2–3%), synthetic amino acids – lysine,

methionine, choline – (0.2–0.7%), coccidiostatics (niacarbazine and natrum monensin), vitamin integrators and oligoelements (0.5%), animal and vegetal fats (5–8%)] + homeopathic concentrations of *S. officinalis* (9CH) (Laboratoires Boiron S.r.l., Milan, Italy, batch number X35826) or 2) standard treatment feed + homeopathic concentrations of Tricalcarea (4CH) (Laboratorio Sodini s.r.l., Florence, Italy, batch number OM1585112) or 3) standard treatment feed + homeopathic concentrations of *C. carbonica* (30CH) (Laboratoires Boiron S.r.l., Milano, Italy, batch number V39462), and 4) standard treatment feed + water (control). The animals were reared in sheds with the same dimensions, internal temperatures, humidity and sun exposure. Details about baseline demographic characteristics of age, weight and bone density of each chicken at entry have been summarized in Table 1.

We carried out a total of 8 treatment cycles at different times. During a whole cycle (45 days), 2 L of solution were poured every 5 days in the 10-hectolitre drinking trough. The solutions were composed of 20 ml *S. officinalis* diluted and dynamized at 9CH (10^{-4}) in 1980 ml of distilled water, 20 ml *C. carbonica* that had been diluted and dynamized at 30CH ($1/10^{-60}$) in 1980 ml of distilled water and 20 ml Tricalcarea diluted and dynamized at 4CH ($1/10^{-60}$) in 1980 ml distilled water, according to the homeopathic method. All the animals were allowed to drink homeopathic solutions and water *ad libitum*.

The chickens were then submitted to CT evaluation (Philips Tomoscan LX 800) at the beginning, after 1 year and at the end of the evaluation. Five different scans were performed for each animal and 4 out of 5 measurements were focused on the sternal spongy tissue. The measurements were obtained from CT images that simultaneously show axial sections of the chicken and the phantom used to calibrate bone mineral contents. Bone mineralization was evaluated by means of a software designed to calculate calcium hydroxyapatite concentration. The specific mineral contents of calcium hydroxyapatite were expressed as mg of calcium hydroxyapatite/ml.

Statistical analysis

Data were analyzed using GraphPad Prism 6 software (GraphPad Software, Inc., La Jolla, CA, USA). All data are presented as the means \pm standard error of the mean and were first checked for normality using the D'Agostino-Pearson normality test. Differences in calcium hydroxyapatite content at the end of treatment versus baseline between the four treatments were analyzed using a one-way analysis of variance (ANOVA) followed by a Tukey's multiple comparisons test.

Results

In Figure 1 the overall improvement of calcium hydroxyapatite in the sternal spongy bone tissue of chickens belonging to all four groups, before and at the end of the 2 years evaluation, is shown (Figure 1).

Table 1 Baseline values of age, weight and sternum spongy-bone density of each group (mean value \pm SD)

Group (n)	Age (mean age \pm SD)	Weight (mean weight \pm SD; gr)	Bone density (mean sternum spongy-bone density \pm SD)
1 (n = 24)	1.2 \pm 0.41	41.53 \pm 1.8	96.1 \pm 5.39
2 (n = 24)	1.25 \pm 0.41	41.32 \pm 1.68	95.5 \pm 4.67
3 (n = 24)	1.16 \pm 0.38	41.45 \pm 1.65	96.03 \pm 5.57
4 (n = 24)	1.12 \pm 0.33	41.35 \pm 1.5	95.73 \pm 5.79

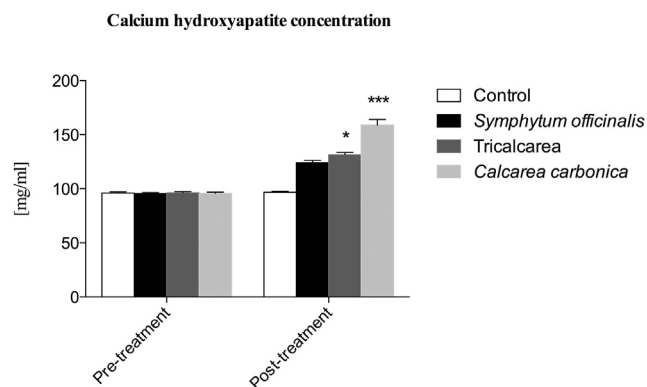


Figure 1 Graphical representation of calcium hydroxyapatite trend before and after the 2 years treatment with *S. officinalis* (9CH), Tricalcareia (4CH) (* $P < 0.05$) and *C. carbonica* (30CH) (** $P < 0.001$) respectively.

Bone mineralization measurements showed that calcium-hydroxyapatite content increased in control samples in proportion with the age, from a baseline value of 96.1 ± 1.1 to 96.71 ± 1.07 mg/ml, but this increase was not statistically significant. This was expected considering that conditions were optimal for growth. A not statistically significant increase of the calcium-hydroxyapatite concentration in the sternum spongy-bone was also observed in the *S. officinalis* (9CH) treated group, from a baseline value of 95.5 ± 0.95 to 124.1 ± 2.11 mg/ml.

As to the Tricalcareia (4CH) treated group, a statistically significant increase of calcium-hydroxyapatite content was observed (* $P < 0.05$), from a baseline value of 96.03 ± 1.14 to 131.2 ± 2.3 mg/ml.

A statistically significant increase was also observed in *C. carbonica* (30CH) treated group (** $P < 0.001$), from a baseline value of 95.73 ± 1.2 to 158.9 ± 5.15 mg/ml.

By comparing control group with the other three groups the sternum spongy-bone mineralization increased by 30% with *S. officinalis* (9CH), 36% with Tricalcareia (4CH) and 63% with *C. carbonica* (30CH).

The average mortality rates of the chickens was 8.5% in the control group and 7% in those treated with homeopathic remedies.

Discussion

Bone tissue mineralization is usually low in battery chickens reared in commercial poultry-sheds which can create a weakness of the whole animal supporting apparatus bearing also important negative consequences on the chicken. Thus, the administration of homeopathic con-

centrations of specific substances, endowed with bone-tissue tropism, could improve the health quality of reared animals.

We studied the effect of vegetable and mineral origin substances on the concentration of calcium hydroxyapatite in the sternal spongy bone tissue of chickens.

These substances were diluted and dynamized according to homeopathic techniques. The process of dilution and the vigorous shaking (succussion) of the substances is called potentization and is performed in order to charge and exponentially energize the substance which becomes more therapeutically active.¹² This process also reduces the chemical toxicity associated with the substances being administered because of several dilutions.

The application of substances in homeopathic concentrations to animals offers a double advantage: first, the possibility to analyse the biological effect of the active principles, diluted and dynamized according to homeopathic techniques, on organisms without considering the placebo effect; second, the enabling of a qualitative improvement of all products of animal origin used for human nutrition. Further, in spite of most of literature reports are focused on the study of evolution and treatment of osteoporosis only few studies evaluated the process of bone repair in osteoporotic individuals. The full impact of osteoporosis on the consolidation of bone fractures is still not completely understood, and it is possible that the drugs used for its treatment may interfere with the repair process. Thus, studies on alternative treatments for osteoporosis are necessary, valid, can contribute to a better understanding of the disease and may improve the quality of life of osteoporotic individuals. There are many alternative treatment options that could offer equivalent results, with less complications and side effects, which deserve to be explored in more depth.

Conclusion

We conclude that *S. officinalis* (9CH), *C. carbonica* (30CH) and Tricalcareia (4CH), administered to chickens in homeopathic dilution, caused a significant increase of calcium-hydroxyapatite concentration in their sternum spongy-bone. Moreover, the three groups treated with *S. officinalis* (9CH) or *C. carbonica* (30CH) or Tricalcareia (4CH) had increased calcium-hydroxyapatite concentration that did not seem dependent on sample age but rather on the presence of these substances in homeopathic dilution. These substances already cause a modest increase of calcium-hydroxyapatite concentration in sternum

spongy-bone of the younger groups, confirming that they produce swift bone mineralization.

In conclusion, this study suggests that traditionally used homeopathic remedies for bone pathologies have a positive and measurable effect on chicken bone maturation, particularly during the first 40–45 days of life.

These preliminary observations may encourage further research into the benefits of a large scale use of osteo-stimulating substances such as *S. officinalis* (9CH), *C. carbonica* (30CH) and Tricalcarea (4CH) in veterinary medicine.

Statement of authorship

The authors hereby certify that all work contained in this article is original. The authors claim full responsibility for the contents of the article.

Conflict of interest statement

The authors certify that there is no conflict of interest with any financial organization regarding the material discussed in the manuscript.

Acknowledgements

The authors contributed equally to this work. This article was not supported by grants.

References

- Rath NC, Huff GR, Huff WE, Balog JM. Factors regulating bone maturity and strength in poultry. *Poult Sci* 2000; **79**(7): 1024–1032.
- Julian RJ. Rapid growth problems: ascites and skeletal deformities in broilers. *Poult Sci* 1998; **77**(12): 1773–1780.
- Knowles TG, Wilkins LJ. The problem of broken bones during the handling of laying hens – a review. *Poult Sci* 1998; **77**(12): 1798–1802.
- Gregory NG, Wilkins LJ. Skeletal damage and bone defects during catching and processing. In: Whitehead CC (ed). *Bone Biology and Skeletal Disorders in Poultry*. Oxford, UK: Co. CP, 1992.
- Aziz-Abdul TA. Cage layer fatigue is a complicated problem. *World's Poult Sci J* 1998; **14**: 56–58.
- Williams B, Waddington D, Murray DH, Farquharson C. Bone strength during growth: influence of growth rate on cortical porosity and mineralization. *Calcif Tissue Int* 2004; **74**(3): 236–245.
- Mazzuco H, Hester PY. The effect of an induced molt and a second cycle of lay on skeletal integrity of White Leghorns. *Poult Sci* 2005; **84**(5): 771–781.
- Frost R, MacPherson H, O'Meara S. A critical scoping review of external uses of comfrey (*Symphytum* spp.). *Complement Ther Med* 2013; **21**(6): 724–745.
- Tyler ML. In: Santos E (ed). *Homoeopathic Drug Pictures*. 2nd edn; 1992. Sao Paulo.
- Sakakura CE, Neto RS, Bellucci M, Wenzel A, Scaf G, Marcantonio E Jr. Influence of homeopathic treatment with comfrey on bone density around titanium implants: a digital subtraction radiography study in rats. *Clin Oral Implants Res* 2008; **19**(6): 624–628.
- Bach N, Thung SN, Schaffner F. Comfrey herb tea-induced hepatic veno-occlusive disease. *Am J Med* 1989; **87**(1): 97–99.
- Punzo A. Homeopathic medicine: an overview with specific applications for the orthopaedic patient. *Tech Orthop* 2003; **18**: 55–61.
- Rode D. Comfrey toxicity revised. *Trends Pharmacol Sci* 2002; **23**: 497–499.
- Peychev L. Epiphysitis of children and homeopathy. *Pharmacia* 2012; **59**(1–4): 44–48.
- Anshutz EP. *New, old and forgotten remedies*. New Delhi, India: B. Jain Publishers, 1989.
- Blackie M. *Classical homoeopathy*. Beaconsfield, Bucks, England: Beaconsfield Publishers LTD, 1986.
- Clarke JH. *Dictionnary of practical Materia Medica Saffron Walden, Essex*. England: Health Science Press, 1987, pp 1340–1343.
- Tyler ML. *Calcarea phosphorica. Retratos de medicamentos homeopáticos*. São Paulo: Santos, 1992, pp 181–187.
- Voisin H. *Manual de matéria médica para o clínico homeopata*. 2nd edn. São Paulo: Andrei, 1987.
- Senra GS, Werkman C, Rocha RF, Brandão AAH. *Estudo radiográfico do reparo ósseo em ratos SHR com osteoporose utilizando homeopatia e risedronato. Programas e Resumos da 5ª Mostra de pós-graduação da Universidade de Taubaté*. Taubaté: Universidade de Taubaté, 2004, p. 306.
- Kilkenny C, Browne WJ, Cuthill IC, Emerson M, Altman DG. Improving bioscience research reporting: the ARRIVE guidelines for reporting animal research. *J Pharmacol Pharmacother* 2010; **1**(2): 94–99.